

Original Article

Protection of myocardium in streptozotocin-induced diabetic rats by water extracts of Hsian-tsao (*Mesona procumbens* Hemsl.)

Min Yang MD¹, Zhengping Xu PHD¹, Ronghua Zhang MD², Pianhong Zhang MPH³, Yan Weng MD³, Yueliang Shen MD¹ and Xiaoming Zhang MD¹

¹School of Medicine, Zhejiang University, Hangzhou, P.R. China

²Zhejiang Province Center for Disease Control and Prevention, Hangzhou, P.R. China

³The Second Affiliated Hospital of Zhejiang University, School of Medicine, Hangzhou, P.R. China

The myocardial protective effects of water extracts from Hsian-tsao (*Mesona procumbens* Hemsl.) on diabetic rats were investigated. Thirty Sprague-Dawley male rats were randomly divided into three groups, "control group" (n=10) with intraperitoneal saline injection, "diabetic group" (n=10) with 60 mg of intraperitoneal streptozotocin injection per kg of body weight and "Hsian-tsao group" (n=10) with intragastric administration of Hsian-tsao extracts every day for 4 weeks after intraperitoneal streptozotocin injection. Body weight and blood sugar concentrations were measured before and after model induction in the three groups. Thrombospondin-1 (TSP-1) expressions in the myocardium were monitored by immunohistochemistry and rt-RT-qPCR analysis. Myocardial ultrastructural changes were also analyzed by using transmission electron microscopy. Our results demonstrated that diabetic myocardial ultrastructural changes included myofibrillar disarrangements, mitochondria disruption, and an increase in nuclear membrane invaginations. These damages were significantly less severe in the Hsian-tsao group compared with the diabetic group. A significant increase of the TSP-1 expression was also observed in the hearts of the diabetic rats ($p < 0.01$), but it was relatively lower in the Hsian-tsao group than in the diabetic group ($p < 0.01$). It suggested that Hsian-tsao treatment in the diabetic rats effectively prevented the pathological alterations in the myocardium and decreased TSP-1 expression.

Key Words: rat, *Mesona procumbens* Hemsl., diabetic cardiomyopathy, Thrombospondin-1, diabetes

INTRODUCTION

As diabetes becomes an epidemic worldwide, more and more diabetic patients face the problems of morbidity and mortality due to chronic complications.^{1,2} Nearly three fourths of the deaths associated with diabetes are due to cardiovascular complications.³ Diabetic cardiomyopathy is characterized by decreasing contractility of the left ventricle and diminishing ventricular compliance.⁴ Several mechanisms have been proposed, including small and micro-vascular disease, autonomic dysfunction, metabolic derangement as well as the accumulation of glycoprotein and collagen.⁵ However, present evidence point to the development of fibrosis and autonomic dysfunction, which further lead to myocardial hypertrophy, increased myocardial stiffness and thus, diastolic dysfunction.⁶

Thrombospondin-1 (TSP-1) was a matricellular, calcium-binding protein that participates in cellular responses to growth factors, cytokines and injury.⁷ Our previous studies showed that up-regulation of TSP-1 expression in diabetic rodent hearts may play a role in the development of diabetic cardiomyopathy.⁸ The herb *Mesona procumbens* Hemsl., called Hsian-tsao in China, is consumed as a popular herbal drink and jelly-type dessert. It is also used as a herbal remedy in the traditional Chinese medicine and is effective against heart attack, hyperten-

sion, diabetes and muscle pains. Hsian-tsao has several antioxidative components, including stigmasterol, β -sitosterol, oleanolic acid, and ursolic acid.⁹ Some researchers reported that phenolic acids could be the important antioxidant components in Hsian-tsao that has a protective effects against DNA damages in human lymphocytes exposed to hydrogen peroxide and UV irradiation.^{10,11} However, there are no reports on the protective effects of Hsian-tsao extracts in streptozotocin (STZ)-induced diabetic rats.

In our study, we employed STZ - induced diabetic cardiomyopathy in rats because STZ is the most widely used agent that produces diabetes mellitus (DM) and their complications in experimental animals.¹² Furthermore, rats are relatively resistant to atherosclerosis, and thus alteration in cardiac function following STZ treatment is believed to be due to cardiomyopathy.¹³ The aim of the

Corresponding Author: Xiaoming Zhang, MD, School of Medicine, Zhejiang University, 388 Yuhangtang Road, Hangzhou 310058, P.R. China
Tel/Fax: +86-571-88208062
Email: zxm@zju.edu.cn

Manuscript received 26 April 2007. Initial review completed 18 September 2007. Revision accepted 8 November 2007.

present study was to highlight Hsian-tsao's cardioprotective effects in diabetic cardiomyopathy and to determine the relationship between decreased TSP-1 expression in the heart and Hsian-tsao's protective effects on diabetic cardiomyopathy.

MATERIALS AND METHODS

Materials

Dried Hsian-tsao (*Mesona procumbens* Hemsl.) leaves were purchased from Zhangping, Fujian Province. The leaves were first washed to remove sand and debris and then boiled at 100°C with water 20-times the volume of the leaves, for 2 hours. The extraction was evaporated under reduced pressure (34-36 kPa) using a rotary vacuum-evaporator at 40°C and the contents were freeze-dried. The dried extract was pulverized, sieved (100 meshes), sealed in zip plastic bags for future use. When needed, accurately weighed sample of the extract was used to prepare the stock solution.

Animal model induction

Thirty 75-90 day old male Sprague-Dawley (SD) rats with body weight between 150-200g were used for this study. The rats were housed five per cage in an environmentally controlled animal laboratory and maintained on a 12 hours light/dark cycle, at ambient temperature (22-25°C) with 55 ± 10% humidity. They were fed a commercial rat feed and water ad libitum. They were then randomly divided by initial weight into three groups consisting of ten animals in each group.

The blood sample was taken from the caudal vein after the rats were anaesthetized. Blood glucose concentrations were measured by Glucose Electrode Calibrator (MediSense QA2583-3364). Twenty rats fasted for 10 hours before STZ was intraperitoneally injected (60 mg/kg) to induce diabetes; the remaining ten rats also fasted for 10 hours and then received an injection of 0.9% saline as a control group. Forty-eight hours after the injection of STZ, the blood glucose level reached >16 mmol/L, indicating the successful induction of diabetes. Ten diabetic rats were given water extract of Hsian-tsao 1.5 g/kg body weight by intragastric administration. The other ten diabetic rats and the ten in the control group were given the same volume of 0.9% saline solution every day, for 4 weeks. Body weight and blood glucose concentrations were then measured weekly in the three groups. All procedures were conducted with the approval of the local animal care committee.

Transmission electron microscopy

Four weeks after the injection of STZ, three animals per group were anesthetized with a lethal dose of Nembutal. Then thoracic cavities were opened and perfused intracardially with 100 mL saline. Then the heart of each rat was taken out immediately. Immersion fixation was completed on 1mm³ heart tissue in the left ventricle. The samples were rinsed in cold phosphate-buffered saline (PBS) and placed in 2.5% glutaraldehyde at 4°C for 4 hours. The tissue was then rinsed in PBS and post-fixed with 1% osmium tetroxide for 1 hour. After that, tissue was rinsed with distilled water before undergoing a gradient ethanol

dehydration process and was infiltrated using a mixture of one-half propylene oxide and one-half resin overnight. Twenty-four hours later, the tissue was embedded in resin. Sections at 120 nanometer were cut and stained with 4% uranyl acetate for 20 min and 0.5% lead citrate for 5 min.

Real-time quantitative reverse transcription-polymerase chain reaction (rt-RT-qPCR) analysis of TSP-1

At the end of the study (four weeks), another three animals per group were anesthetized with a lethal dose of Nembutal. After perfused intracardially with 100 mL normal saline, the heart of each rat was taken out immediately to obtain fresh tissue specimens. For total RNA isolation, RNA for RT-PCR analysis was isolated from the specimens using the Trizol reagent kit (Gibco Inc., USA) according to the manufacturer's protocol. For reverse transcription, RNA concentration was measured spectrophotometrically and 2 µg total RNA was added to the cDNA synthesis reaction system (20 µL). The reaction mixture consisted of 4 µL 5×RT-Buffer, 2.5 µmol/L oligo (T), 5 mmol/L dNTPs and 20 U RNAasin (RNase inhibitor). The hexamers were annealed by incubating the samples at 70°C for 5 min. After which 200 U of M-MLV reverse transcriptase was added, and then the sample was incubated at 42°C for 60 min. The reaction was stopped by increasing the temperature to 72°C for 10 min. For rt-RT-qPCR, the reaction mixture (40 µL) consisted of 4 µL cDNA, 35.2 µL SYBR Green PCR mix, 0.5 µL 5 U Taq DNA polymerase and 0.3 µL 20 pmol/µL TSP-1 primer. Denaturation of cDNA was achieved by heating at 94°C for 3 min. The template was amplified by 40 rounds of PCR (denaturation at 94°C for 10sec., annealing at 57°C for 30sec, extension at 72°C for 30sec.), before collecting fluorescence at 72°C. Meanwhile, primers were used for the housekeeping gene glyceraldehydes-3-phosphate dehydrogenase (GAPDH) in rt-RT-qPCR to amplify GAPDH as an internal control of TSP-1. Primers used are as follows: TSP-1: forward: GAGTGTCACTGCCA-GAACTCA 5'-3'; reverse: GTCTGTACTGAAGAGCCC TCA 5'-3'. The PCR product length of the TSP-1 is 248 bp.

Semi-Quantitative RT-PCR analysis of TSP-1

These three rats samples were also used for semi-quantitative RT-PCR analysis. Total RNA isolation and reverse transcription were the same as rt-RT-qPCR. For semi-quantitative RT-PCR, the reaction mixture (40 µL) consisted of 4 µL cDNA, 4 µL 10×Buffer, 0.8 µL 10 mM/L dNTP, 4 µL 25 mmol/L MgCl₂, 0.5 µL 5 U Taq DNA polymerase, 1 µL TSP-1 primer, and 24.7 µL de-ionized water. Complementary DNA was denatured by heating at 94°C for 3 min. The template was amplified by 40 rounds of PCR (denaturation at 94°C for 15 sec., annealing at 57°C for 30 sec., extension at 72°C for 30 sec.), and extension at 72°C for 10 min at the end. Then the agarose gel electrophoresis was run. PCR products (5 µL) was loaded along with molecular-weight markers onto an agarose gel which contains 1 µL 6×loading dye (0.8-4.0% ethidium bromide). DNA bands on the gel can then be visualized under ultraviolet trans-illumination. Primer-specific nucleotide sequences for TSP-1 (forward:

GAGTGTCAGTCCAGAACTCA 5'-3'; reverse: GTCTGTACTGAAGAGCCCTCA 5'-3') were used.

Immunohistochemistry

Immunohistochemistry was used to localize TSP-1 antigens. At first, the remaining four rats were anesthetized with a lethal dose of Nembutal. Then their thoracic cavities were opened and perfused intracardially with normal saline. Following saline perfusion, the animals were perfused with 300–400 mL fixative containing 4% paraformaldehyde in 0.1 M phosphate buffer (pH 7.4). After perfusion, the heart of each rat was taken out. These tissues were fixed in the same fixative for 4 hours and then placed in 30% phosphate buffered sucrose until the tissue sank. Eight- μ m-thick sections were cut on freezing microtome through coronary planes of the heart. Sections were then rinsed in 0.01 M PBS and mounted onto 0.02% poly-L-lysine-coated slides.

The Avidin Biotin-Peroxidase Complex technique (ABC) system was used with 3, 3'-diaminobenzidine hydrochloride (DAB) as the chromagen. Briefly, tissue sections were washed in PBS, incubated in 1% bovine serum albumin (BSA) for 30 min, and then incubated overnight at 4 °C in the primary antibody (monoclonal TSP-1 antibody, Oncogene Company) plus 1% BSA in PBS. The dilutions of the primary antibody were 1:100. Control sections were incubated in PBS. The next day, the sections were incubated in a biotinylated goat anti-mouse secondary antibody (diluted to 1:200 in PBS), and subsequently in an avidin-HRP solution. Immunolabeling was visualized with 0.05% DAB plus 0.3% H₂O₂ in PBS. The sections were then dehydrated through ethanol and xylene before coverslipped with Permount.

Image analysis and statistics

For transmission electron microscopy, images were captured from random sections using a TECNAI 10 transmission electron microscope at 80 kV. For immunohistochemistry, the left ventricular tissues were selected on each slide and examined at magnification of 400 times with UTHSCSA Image Tool 3.0 (University of Texas Medical School at San Antonio, TX, USA). The number and optical density of the TSP-1 positive cells were measured. All data were given as mean \pm SD. Statistical analysis was performed using SPSS for windows 10.0, statistical software. Significance of difference between

Table 1. Body weight and blood glucose levels of the Hsian-tsao group, Diabetic group, and Control group of rats.

Groups	Body weight (g)	Blood glucose (mmol/L)
Before STZ injection		
Hsian-tsao	164 \pm 7	3.9 \pm 0.4
Diabetic	164 \pm 6	3.8 \pm 0.5
Control	166 \pm 6	3.7 \pm 0.5
Four weeks after STZ injection		
Hsian-tsao	235 \pm 22* [#]	18.9 \pm 2.9* [#]
Diabetic	189 \pm 18*	23.5 \pm 5.6*
Control	261 \pm 32	4.0 \pm 0.7

Values are expressed as mean \pm SD (n=10); * $p < 0.01$ vs. Control group; [#] $p < 0.01$ vs. Diabetic group

the groups was evaluated using T-test. For multiple comparisons, one-way analysis of variance (ANOVA) was used. In case ANOVA shows significant differences, post-hoc analysis was performed with Student-Newman-Keuls (SNK) test. P values were two tailed and $p < 0.05$ was considered as significant.

RESULTS

Body weight and blood glucose

Body weight and blood glucose showed no significant differences ($p > 0.05$) among the three groups of rats before STZ injection. At the end of the study (4 weeks), the Hsian-tsao group had a significantly higher body weight ($p < 0.01$) and lower blood glucose ($p < 0.01$) compared to the diabetic group. (Table 1)

Transmission electron microscopy

Diabetes induced several visible and distinct changes in the ultrastructure of the cardiomyocyte. When compared with the control group, samples from the left ventricle of the diabetic rat showed disordered myofibrils and swollen mitochondria (Fig 1). The nucleus of diabetic cardiomyocyte also had morphological changes, including an increase in invaginations and heterochromatin accumulation (Fig 2). The Hsian-tsao group has relatively lower damages than the diabetic group (Fig 1, Fig 2).




Figure 1. Morphology images of the cardiomyocyte myofibrils and mitochondria. A: Diabetic group $\times 8900$, B: Control group $\times 8900$, C: Hsian-tsao group $\times 8900$.

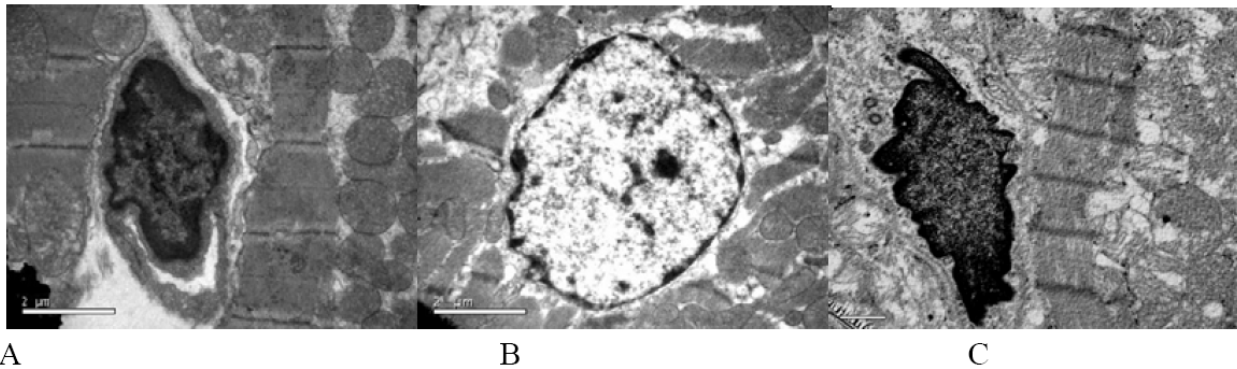


Figure 2. Morphology images of the cardiomyocyte nuclei. A: Diabetic group $\times 8900$, B: Control group $\times 8900$, C: Hsian-tsao group $\times 8900$.

Table 2. Relative quantization using the comparative C_T method.

Groups	TSP-1 Ave C_T	GAPDH Ave C_T	Normalized TSP-1 Exp. (ΔC_T) TSP-1-GAPDH	Calibrated TSP-1 Exp. ($\Delta\Delta C_T$) $\Delta C_T - \Delta C_T^{\text{control}}$	Fold Difference $2^{-(\Delta\Delta C_T)}$
Hsian-tsao	27.5 ± 0.05	17.7 ± 0.09	9.81	-0.52	1.43
Diabetic	27.3 ± 0.06	18.9 ± 0.06	8.47	-1.86	3.63
Control	29.0 ± 0.05	18.7 ± 0.06	10.3	0.00	0

Values are expressed as mean \pm SD (n=3)

TSP-1 mRNA levels in the Diabetic group was about 3.63 times more than that in the Control group while the Hsian-tsao group was about 1.43 times more.

Assessment of TSP-1 mRNA level

The Semi-Quantitative RT-PCR results proved a decreased TSP-1 mRNA level in the Hsian-tsao group when compared to the diabetes group, but it was higher than the level in control group, as shown by the optical density of the TSP-1 PCR product in agarose gel electrophoresis (610 ± 12.4 vs. 677 ± 13.6 and 426 ± 11.3). The differences among the three groups were significant ($p < 0.01$) (Fig 3).

The rt-RT-qPCR results show that the TSP-1 mRNA level is down-regulated in the Hsian-tsao group, compared to the diabetes group, as indicated by the increased ΔC_T values, and to be specific, the TSP-1 mRNA level in diabetes group is more than 3.63 times that of the control group and the Hsian-tsao group is more than 1.43 times

that of the control group (Table 2).

Immunohistochemistry

In heart tissues of the diabetic rats, the myocardium had hypertrophy and structure rarefaction. TSP-1 immunohistochemistry staining positive cells showed buffy granule with DAB staining. The myocardium, extracellular matrix and the endothelial cells of the small vessels between myocardium all showed increased TSP-1 expression when compared with the control group. It can be observed that the subendothelial matrix of myocardial small vessels was thickened and expressed TSP-1 intensively. Hsian-tsao supplementation in these animals were seen to decrease the number of TSP-1 positive cells and the optical density of the TSP-1 immunostaining myocardium, compared with the diabetic rats ($p < 0.01$).

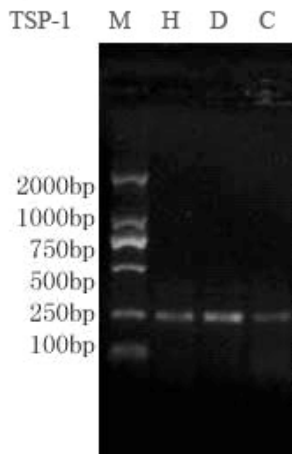


Figure 3. Assessment of the TSP-1 mRNA level. Agarose gel electrophoresis of TSP-1 by RT-PCR. M: marker, H: Hsian-tsao group, D: Diabetic group, C: Control group.

DISCUSSION

Diabetic cardiomyopathy is the most dangerous complication facing diabetics.¹⁻³ Although some factors have been considered to determine the risk of cardiovascular complications in diabetes mellitus,^{5,6} the exact underlying mechanism is still controversial.

Thrombospondin (TSP) is a multifunctional protein that exists both as a secreted protein and an insoluble extracellular matrix molecule. TSP-1, the best-characterized member of the family of five thrombospondin isoforms, is a major component of platelet α -granules. TSP-1 acts as an immediate early response gene, being rapidly up-regulated in response to serum and growth factors such as tumor growth factor- β (TGF- β) and platelet-derived growth factor (PDGF). It was also newly reported that there exists a TSP-dependent mechanism of TGF- β activation.¹⁴⁻¹⁶ TGF- β is a group of potent regulatory cytokines involved in many biological processes.¹⁷⁻¹⁹ Cell

Table 3. The number of TSP-1 positive cells and the optical density of TSP-1 immunostaining myocardium in different groups of rats.

Groups	TSP-1 positive cells (mm ²)	TSP-1 immunostaining myocardium
Hsian-tsao	14.3 ± 1.8* [#]	82.7 ± 5.3* [#]
Diabetic	17.3 ± 2.1*	103 ± 9.3*
Control	10.1 ± 2.6	61.2 ± 6.7

Value are expressed as mean ± SD (n=4); * $p < 0.01$ vs. Control group; [#] $p < 0.01$ vs. Diabetic group

culture studies have indicated that TGF- β inhibits mitotic growth of cardiomyocytes,²⁰ stimulates hypertrophic growth²¹ and fibrosis.^{22,23} Under diabetic condition, there is an increased production of TGF- β proteins and an increase in TGF- β activity. ANG II and hyperglycaemia can stimulate the TGF- β gene activation through protein kinase C (PKC) and p38 MAPK-dependent pathways. On the other hand, TGF- β potentiates the c-fos serum response element (SRE) activated by PKC through the serum response factor (SRF) binding site. TGF- β is thus involved in the regulation of c-fos gene expression through the c-fos SRE and is subsequently involved in the regulation of the gene which has the TPA response element (TRE) in the promoter/enhancer region.²⁴ Another recent study has confirmed that glucose-induced activation of TGF- β is dependent on PKC activity, leading to a sequential increase in TSP-1 synthesis in cultured human mesangial cells and proposed high glucose conditions which induce an increase in PKC-TGF- β -TSP-1 pathway. Glucose-induced increase in TSP-1 may facilitate TGF- β activation in an autocrine manner in cultured human mesangial cells.²⁵ Given the well-established participation of TGF- β in various diabetic complications, including cardiomyopathy, our research showed that TSP-1 expression increased in diabetic myocardium, and it is very likely that TSP-1 has a role, through the PKC-TGF- β -TSP-1 pathway and the mutual activation between TGF- β and TSP-1, in the development of diabetic cardiomyopathy.⁸ In the present study, we found that TSP-1 expression was significantly down-regulated in the Hsian-tsao group compared to that in the diabetic group. This revealed that Hsian-tsao might prevent myocardium in diabetic rats by decreasing TSP-1 expression. Further research should focus on the activators of TSP-1, such as TGF- β and PKC expression, in the myocardium of diabetic rats to explore the influence of Hsian-tsao on the PKC-TGF- β -TSP-1 pathway.

In this study we also used electron microscopy and immunohistochemistry to determine the expression of TSP-1 in the heart after 4 weeks of diabetic induction and to demonstrate the protective effects of Hsian-tsao in the development of diabetic cardiomyopathy in experimental diabetes. We found disordered myofibrils and swollen mitochondria in diabetic rats, as well as morphological changes in the nucleus of diabetic cardiomyocytes. Including an increase in invaginations and heterochromatin accumulation in diabetic rats. The damages were relatively lower in the Hsian-tsao group than that in diabetic group. Hsian-tsao administration prevented the pathological changes as observed in the diabetic group. Hsian-tsao

extracts contains antioxidative and free radical scavenging components, such as tigmasterol, β -sitosterol, oleanolic acid, and ursolic acid.⁹ It was reported that the antioxidative activity of a water extract of Hsian-tsao was higher than that of α -tocopherol and BHT.²⁶ Some scientists found that Hsian-tsao had protective effect on DNA damage in human lymphocytes exposed to hydrogen peroxide and UV irradiation. The protective effect might be due to the fact that it contains polyphenol compounds and/or other active components.¹¹ We have previously shown that Hsian-tsao had strong antioxidative and antimutagenic effects.²⁷ Therefore, we propose that Hsian-tsao administration in the early stages of the cardiomyopathy might prevent the appearance of subsequent clinical symptoms, through the reversal of functional and morphologic abnormalities in the hearts of diabetic rats. This is possibly due to the different mechanisms associated with different antioxidants existing in Hsian-tsao. The exact mechanisms and constituents need further investigation.

ACKNOWLEDGEMENTS

This research was supported by the Science Found of Zhejiang Province (2004C32082) and Natural Science Foundation of Zhejiang province (No. Y204036). The authors are grateful to Mrs. Caiju Xu and Mrs. Jia Men of the Zhejiang Province Center for Disease Control and Prevention, Hangzhou, China, for their animal model preparation assistances.

AUTHOR DISCLOSURES

Min Yang, Zhengping Xu, Ronghua Zhang, Pianhong Zhang, Yan Weng, Yueliang Shen and Xiaoming Zhang, no conflicts of interest.

REFERENCES

- Harris MI. Diabetes in America: epidemiology and scope of the problem. *Diabetes Care*. 1998;21:C11-14.
- Zimmer P. Globalization, coca-colonization and chronic disease epidemic: can the doomsday scenario be averted? *J Int Med*. 2000;247:301-310.
- Geiss LS, Herman WH, Smith PJ. Mortality in non-insulin-dependent diabetes. In: Harris MI, editor. *Diabetes in America*, National Health Institute (Publication 95-C1468). Bethesda; 1995;233-257.
- Fein FS, Cho S, Zola BE, Miller B, Factor SM. Cardiac pathology in the hypertensive diabetic rat. Biventricular damage with right ventricular predominance. *Am J Pathol*. 1989; 134:1159-1166.
- Haider B, Yeh CK, Thomas G, Oldewurtel HA, Lyons MM, Regan TJ. Influence of diabetes on the myocardium and coronary arteries of rhesus monkey fed anatherogenic diet. *Circ Res*. 1981;49:1278-1288.
- Spector KS. Diabetic cardiomyopathy. *Clin Cardiol*. 1998;21: 885-887.
- Chen H, Herndon ME, and Lawler J. The cell biology of thrombospondin-1. *Matrix Biol*. 2000;19:597-614.
- Zhang XM, Shen F, Xv ZY, Yan ZY, Han S. Expression changes of thrombospondin-1 and neuropeptide Y in myocardium of STZ-induced rats. *Int J Cardiol*. 2005;105(2): 192-197.
- Hung CY and Yen GC. Extraction and Identification of Antioxidative Components of Hsian-tsao (*Mesona procumbens* Hemsl.). *Lebensm.-Wiss. u.-Technol*. 2001;34:306-311.
- Hung CY, and Yen GC. Antioxidant activity of phenolic compounds isolated from *Mesona procumbens* Hemsl.. *J Agric Food Chem*. 2002;50:2993-2997.

11. Yen GC, Hung YL, and Hsieh CL. Protective effect of extracts of *Mesona procumbens* Hemsl. on DNA damage in human lymphocytes exposed to hydrogen peroxide and UV irradiation. *Food Chem Toxicol.* 2000;38:747-754.
12. He RX, Gu CL, Shen F, Zhang XM. Changes in expression of adrenomedullin in the myocardium of streptozotocin-induced diabetic rats. *Chin Med J (Engl).* 2007;120:187-191.
13. Tomlinson KC, Gardiner SM, Hebden RA, Bennett T. Functional consequences of streptozotocin-induced diabetes mellitus, with particular reference to the cardiovascular system. *Pharmacol Rev.* 1992;44:103-150.
14. Adams JC, Tucker RP, Lawler J. The Thrombospondin Gene Family. Molecular Biology Intelligence Unit, R. G. Landes Co, Austin, Texas, 1995.
15. Frazier WA. Thrombospondins. *Curr Opin Cell Biol.* 1991;3:792-799.
16. Bornstein P. Thrombospondins-structure and regulation of expression. *FASEB J.* 1992;6:3290-3299.
17. Massague J. The transforming growth factor- β family. *Annu Rev Cell Biol.* 1990;6:597-641.
18. Roberts AB. Transforming growth factor- β : activity in animal models of wound healing. *Wound Repair Regen.* 1995;3:408-418.
19. Lawrence DA. Transforming growth factor- β : a general review. *Eur Cytokine Network.* 1996;7:363-374.
20. Kardami E. Stimulation and inhibition of cardiac myocyte proliferation in vitro. *Mol Cell Biochem.* 1990;92:129-135.
21. Villarreal FJ, Dillmann WH. Cardiac hypertrophy-induced changes in mRNA levels for TGF-beta 1, fibronectin, and collagen. *Am J Physiol.* 1992;262:H1861-866.
22. Eghbali M, Tomek R, Sukhatme VP, Woods C, Bhambi B. Differential effects of transforming growth factor-beta 1 and phorbol myristate acetate on cardiac fibroblasts: regulation of fibrillar collagen mRNAs and expression of early transcription factors. *Circ Res.* 1991;69:483-490.
23. Parker TG, Packer SE, Schneider MD. Peptide growth factors can provoke "fetal" contractile protein gene expression in rat cardiac myocytes. *J Clin Invest.* 1990;85:507-514.
24. Joanne E, Murphy-Ullrich, Maria P. Activation of latent TGF- β by thrombospondin-1: mechanisms and physiology. *Cytokine Growth F R.* 2000;11:59-69.
25. Tada H, Kuboki K, Nomura K, Inokuchi T. High glucose levels enhance TGF-beta1-thrombospondin-1 pathway in cultured human mesangial cells via mechanisms dependent on glucose-induced PKC activation. *J Diabetes Complications.* 2001;15(4):193-197.
26. Lai LS, Chou ST, and Chao WW. Studies on the antioxidative activities of Hsian-tsao (*Mesona procumbens* Hemsl.) leaf gum. *J Agric Food Chem.* 2001;49:963-968.
27. Yang M. Protection of Hsian-tsao (*Mesona procumbens* Hemsl.) on H₂O₂-induced DNA damage of primarily cultured mice spleen lymphocytes. *Zhejiang Da Xue Xue Bao Yi Xue Ban.* 2006;35(1):34-38.

Original Article

Protection of myocardium in streptozotocin-induced diabetic rats by water extracts of Hsian-tsao (*Mesona procumbens* Hemsl.)

Min Yang MD¹, Zhengping Xu PHD¹, Ronghua Zhang MD², Pianhong Zhang MPH³, Yan Weng MD³, Yueliang Shen MD¹ and Xiaoming Zhang MD¹

¹School of Medicine, Zhejiang University, Hangzhou, P.R. China

²Zhejiang Province Center for Disease Control and Prevention, Hangzhou, P.R. China

³The Second Affiliated Hospital of Zhejiang University, School of Medicine, Hangzhou, P.R. China

仙草水提物对链脲酶素诱导糖尿病大鼠心肌的保护作用

本研究目的是观察仙草(*Mesona procumbens* Hemsl.)水提取物对糖尿病大鼠心肌的保护作用。30只雄性SD大鼠随机分为3组,对照组(n=10)腹腔注射生理盐水,糖尿病组大鼠(n=10)腹腔注射链脲酶素(60mg/Kg),仙草组(n=10)腹腔注射链脲酶素后每天仙草提取物灌胃连续4周。于实验前和成模4周后分别测量3组大鼠体重、血糖浓度的变化。成模4周后,处死大鼠在透射电镜下观察各组大鼠心肌超微结构的改变;同时采用免疫组化和rt-RT-qPCR分析的方法测定各组大鼠心肌血小板反应素-1的表达情况。实验结果显示:糖尿病大鼠心肌超微结构的变化包括心肌纤维排列紊乱,线粒体崩解和核膜内陷增加;与糖尿病大鼠比较,仙草组心肌损伤明显较轻。实验同时发现糖尿病大鼠心脏中血小板反应素-1的表达明显增加($p < 0.01$),而仙草组的增加量明显小于糖尿病组大鼠($p < 0.01$)。上述结果提示仙草干预可有效预防糖尿病大鼠的心脏病变,降低血小板反应素-1的表达。

关键词:大鼠、仙草、糖尿病的心肌病、血小板反应素-1、糖尿病。